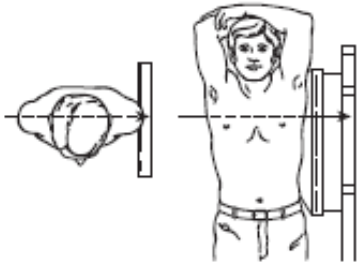
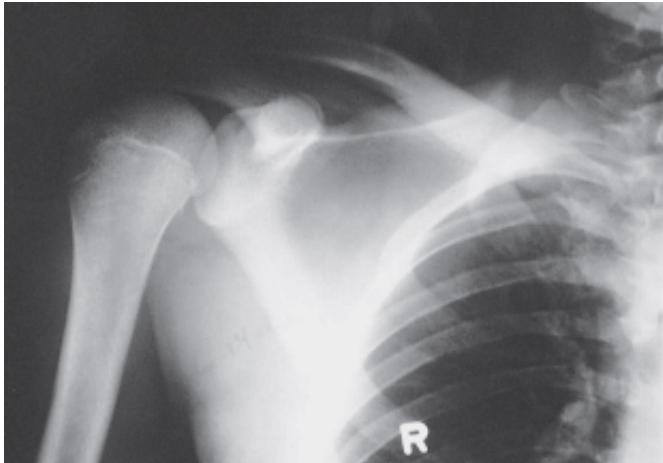
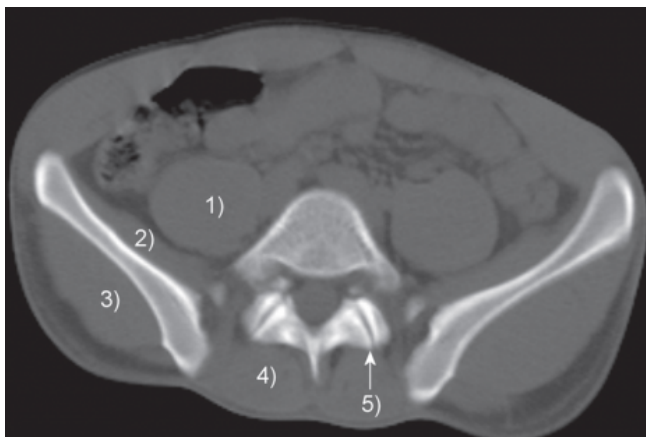

FRCPT FIRST BATCH – FINAL EXAMINATION (← BACK TO COURSE)

(HTTP://DIGITALTEACHING.ORG/COURSE/FRCPT-ONLINE-COURSE/)

**1. What is this exact projection?****Marked Answer :** Left Lateral Projection**Correct Answer :** LEFT LATERAL PROJECTION**TOTAL MARKS : 5**
MARKS OBTAINED ✓ 5**2. What is the exposure in gleno-humeral joint in this X Ray?****Marked Answer :** Properly Exposed**Correct Answer :** PROPERLY EXPOSED +**TOTAL MARKS : 5**
MARKS OBTAINED ✓ 5

3. What is the structure marked '5' in the CT?



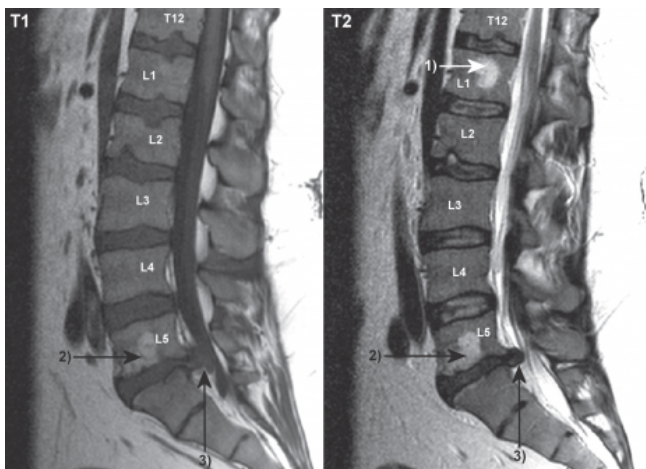
Marked Answer : Facet Joint

Correct Answer : FACET JOINT

MARKS OBTAINED ✓ 5

TOTAL MARKS : 5

4. What is the phenomenon marked 1 in this MRI?

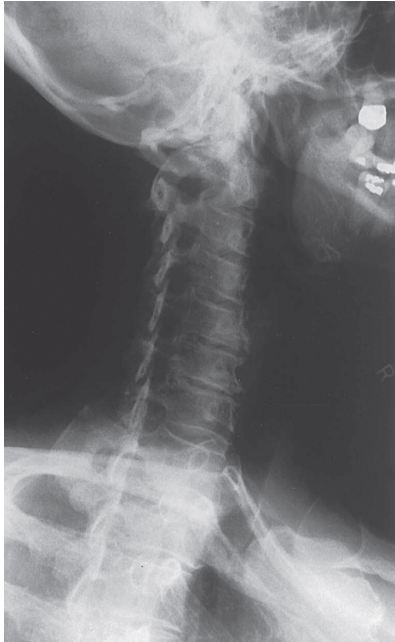
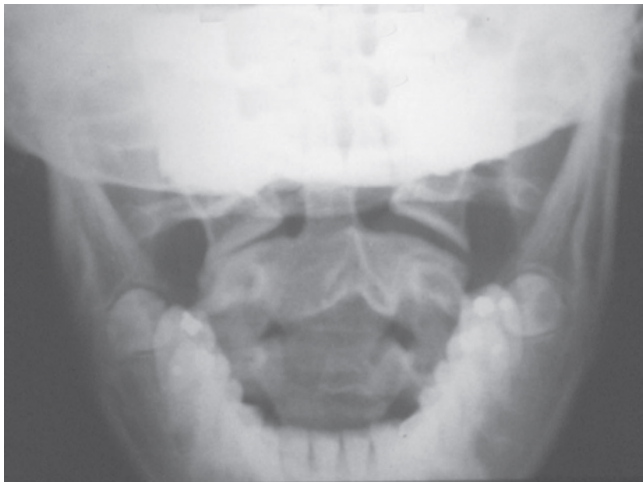
Marked Answer : Fluid

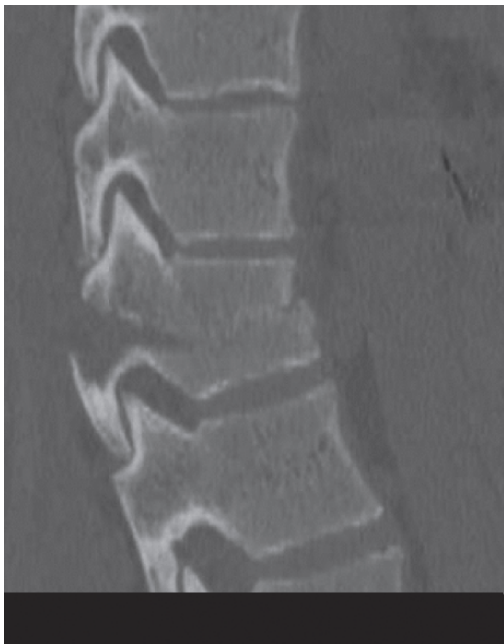Correct Answer : FLUID

MARKS OBTAINED ✓ 5

TOTAL MARKS : 5

5. What anatomic feature is best assessed on this view?**Marked Answer :** Vertebral Body**Correct Answer :** INTERVERTBRAL FORAMINA +**TOTAL MARKS : 5**
MARKS OBTAINED ✕ 0**6. Is the axis rotated? To which side?****Marked Answer :** Yes, Axis is rotated to Left**Correct Answer :** YES, AXIS IS ROTATED TO RIGHT +**MARKS OBTAINED ✕ 0** **TOTAL MARKS : 5**

7. What kind of injury could cause kind of 'Chance or Seatbelt Fracture'?

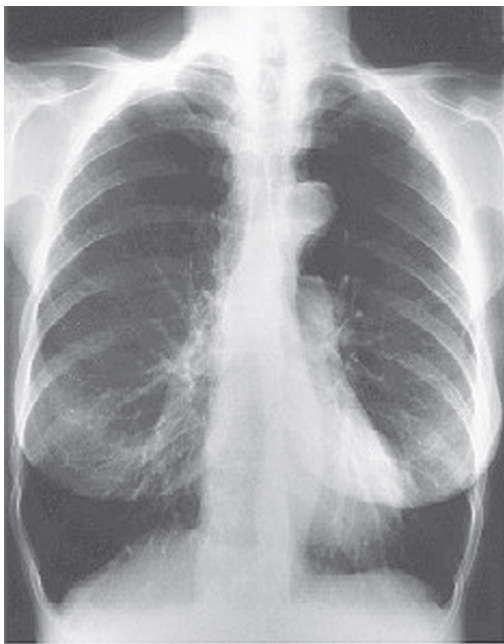

Marked Answer : Hyper-Flexion Injury

Correct Answer : HYPER-FLEXION INJURY +

TOTAL MARKS : 5
MARKS OBTAINED ✓ 5

8. What projection is this?



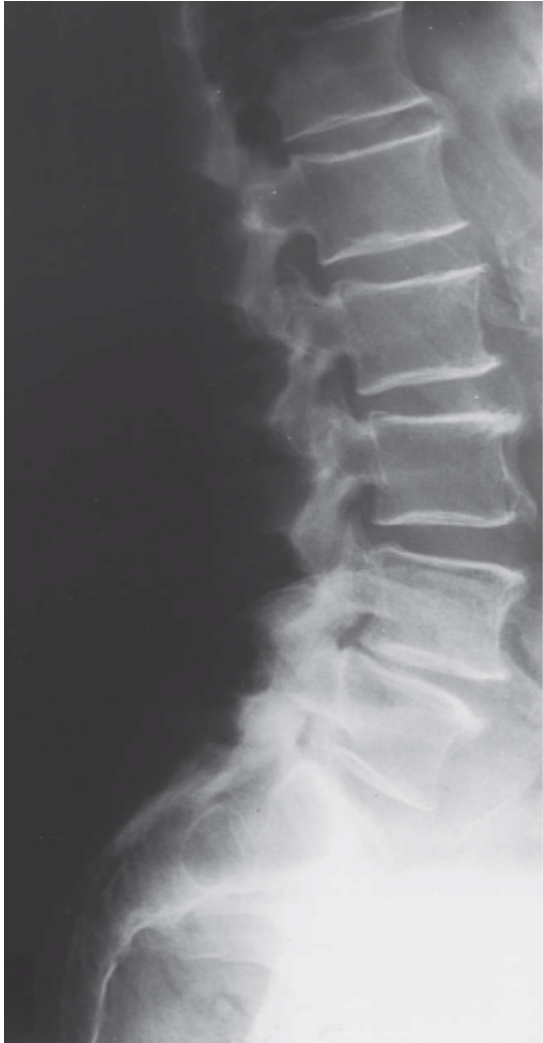Marked Answer : PA

Correct Answer : PA +

MARKS OBTAINED ✓ 5

TOTAL MARKS : 5

9. Which intervertebral disk spaces are narrowed?

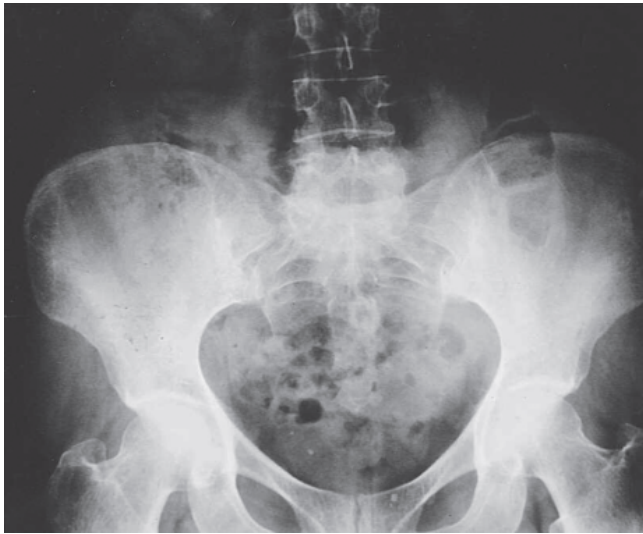


Marked Answer : L4-L5 & L5-S1

Correct Answer : L4-L5 & L5-S1 +

TOTAL MARKS : 5
MARKS OBTAINED ✓ 5

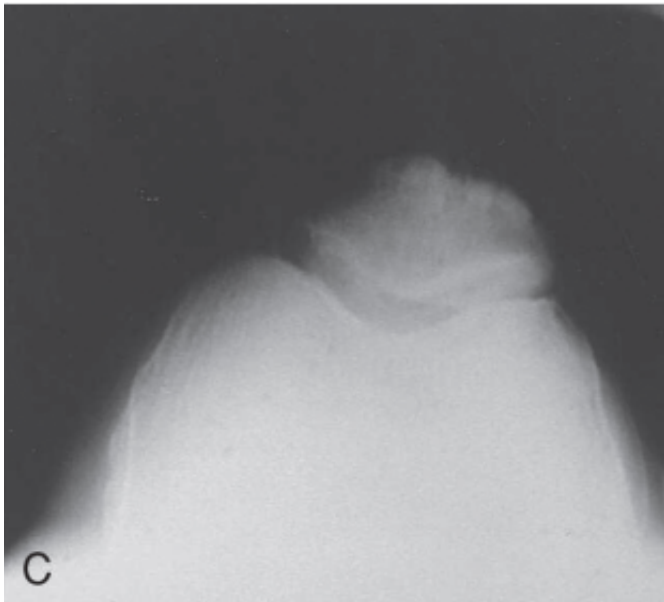
10. Based on the bony configuration of the pelvis and the pelvic inlet, would you guess this patient is male or female?



Marked Answer : Male Correct Answer : NOT POSSIBLE TO DETERMINE +

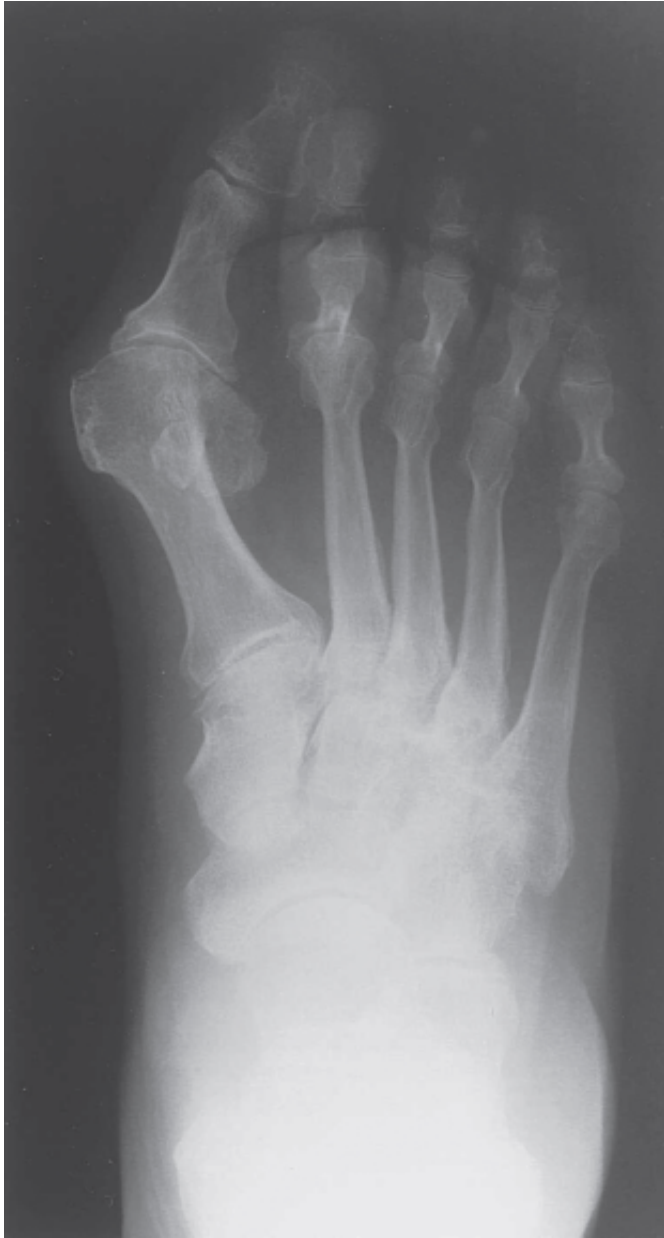TOTAL MARKS : 5
MARKS OBTAINED X 0

11. Which part of the body or what phenomenon is this X Ray?



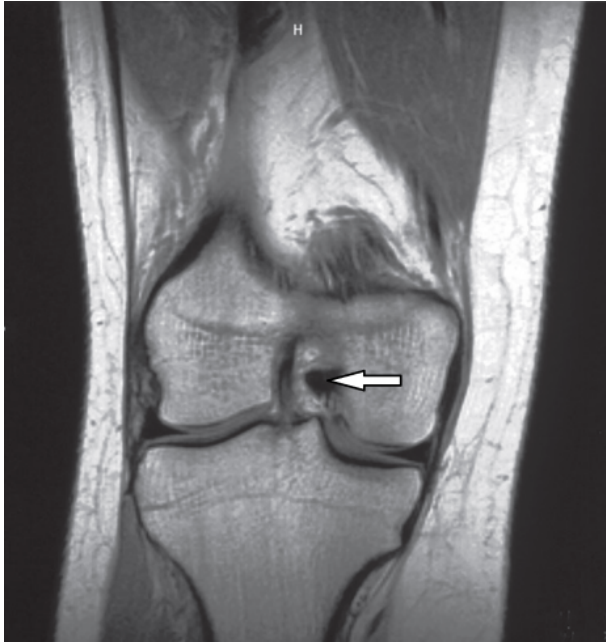
Marked Answer : Knee Correct Answer : KNEE +

MARKS OBTAINED ✓ 5 TOTAL MARKS : 5

12. Name the deformity at the first digit?

Marked Answer : Hallux Valgus **Correct Answer :** HALLUX VALGUS +

TOTAL MARKS : 5
MARKS OBTAINED ✓ 5

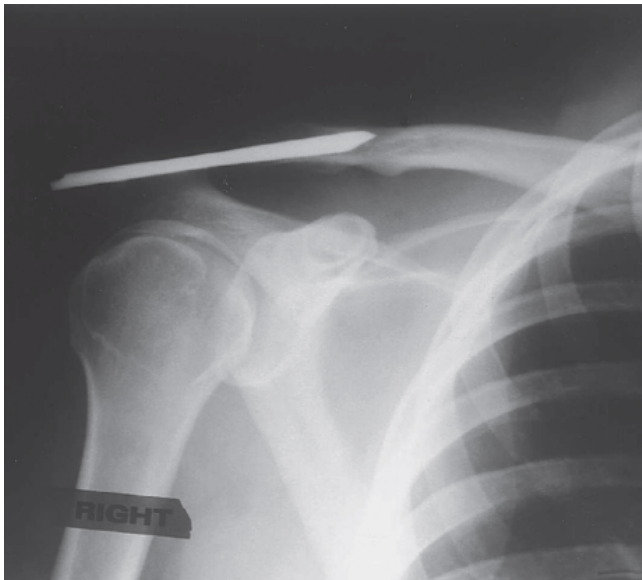
12. What is the structure marked in this MRI?

Marked Answer : Posterior Cruciate Ligament

Correct Answer : POSTERIOR CRUCIATE LIGAMENT

MARKS OBTAINED ✓ 5

TOTAL MARKS : 5

14. What joint is being stabilized by the internal fixation device?

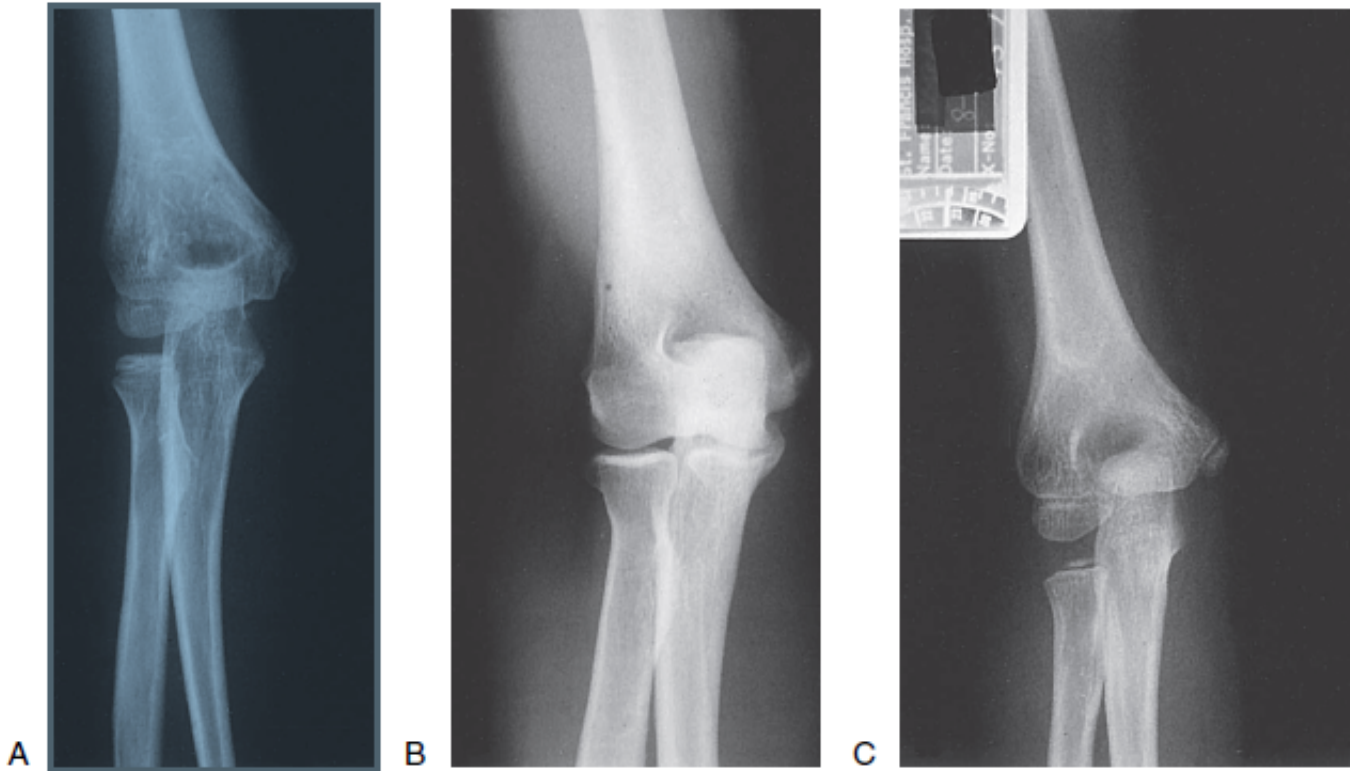
Marked Answer : The acromioclavicular joint

Correct Answer : THE ACROMIOCLAVICULAR JOINT

MARKS OBTAINED ✓ 5

TOTAL MARKS : 5

15. All the following three films represent normal findings in AP projections of left elbow for different age groups [5-year-old girl, the 10-year-old boy, and the 30-year-old man]. Identify which belongs to 10 years old boy.



Marked Answer : A Correct Answer : A

MARKS OBTAINED ✓ 5 TOTAL MARKS : 5

Total Marks

60 / 75